

## 6-year-old girl with upper-limb swelling

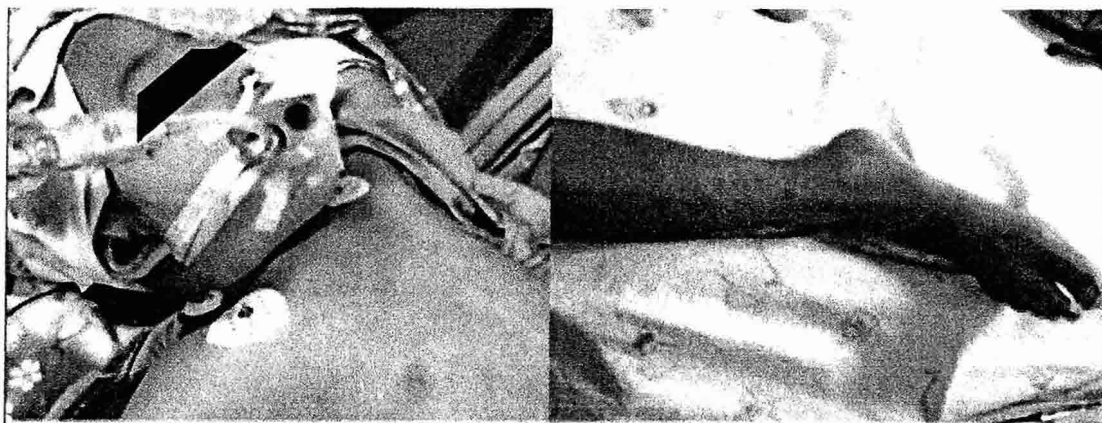
Pimpak Prachasilchai, Worakan Promphan, Thanarat Layangool

Queen Sirikit National Institute of Child Health, College of medicine, Rangsit University, Bangkok, Thailand

A 6-year-old girl presented with dyspnea and fatigue. Two weeks prior, she had developed bilateral, upper-limb and neck swelling (Figure 1). A systolic ejection murmur was noted at the left upper sternal border. She had differences in blood pressure, which was lower at the lower limb. A chest x-ray revealed cardiomegaly (Figure 2). An electrocardiogram demonstrated left ventricular hypertrophy. An echocardiographic examination revealed a left-ventricular, systolic dysfunction and a narrowing of the aorta from the thoracic to the abdominal level (Figure 3). Takayasu disease was suspected. The girl's condition deteriorated. A cardiac catheterization was performed. A diagnosis of long-segment, severe narrowing at the thoracic aorta (6 cm long) and a moderate to severe supra-renal aorta (4 cm long) were confirmed (Figures 4, 5). There was also stenosis in the proximal, left renal artery. The gradient across the lesion was 86 mmHg. The narrow segment was stented with a 9 x 55 mm CO-CR peripheral stent (Figure 6). At the lower segment of the lesion and at the proximal left renal artery, balloon inflation was performed using the balloon from the stent and a 3 x 20 mm Mozec PTCA balloon until the waist disappeared, with a residual aorta gradient of 4 mmHg (Figures 7, 8). Doing well without swelling, the girl was discharged. Medication for Takayasu disease was given. At the one-month follow-up, she had an improved cardiac function and no blood pressure difference.

### Discussion

Takayasu disease is rare, and this case is an unusual manifestation. The stent implantation was the rescue treatment for this patient. Long-term follow up will be crucial.



เสนอโดยนางสาวพิมพ์ภัค ประชาศิลป์ชัย นายแพทย์ปฏิบัติการ สถาบันสุขภาพเด็กแห่งชาติมหาราชินี

ในการประชุม Congenital & Structural Interventions

ซึ่งจัดขึ้นระหว่างวันที่ 25 - 29 มิถุนายน 2557 ณ สหพันธ์สาธารณรัฐเยอรมนี

Figure 1

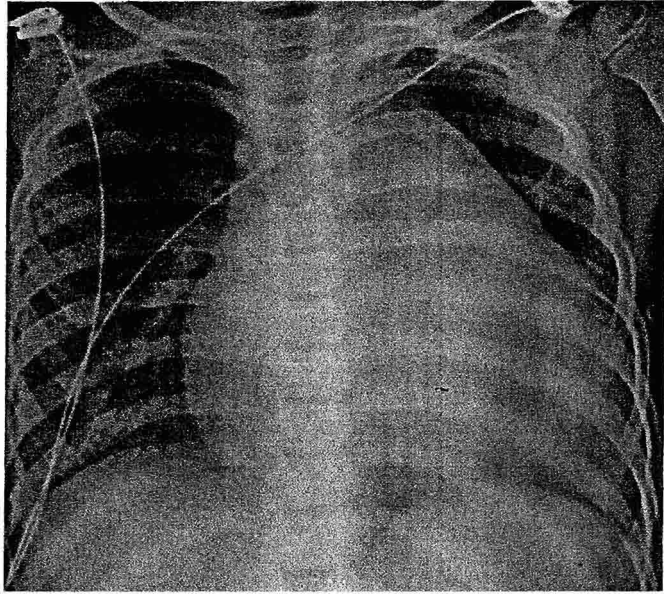


Figure 2

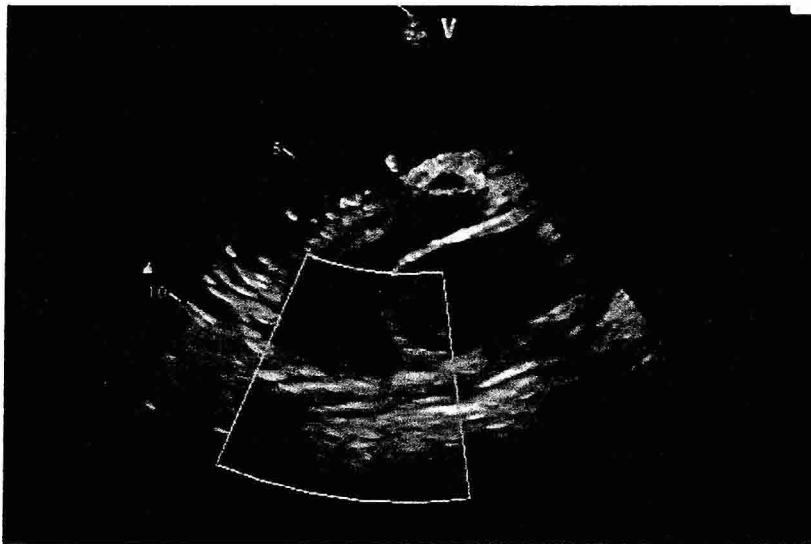


Figure 3

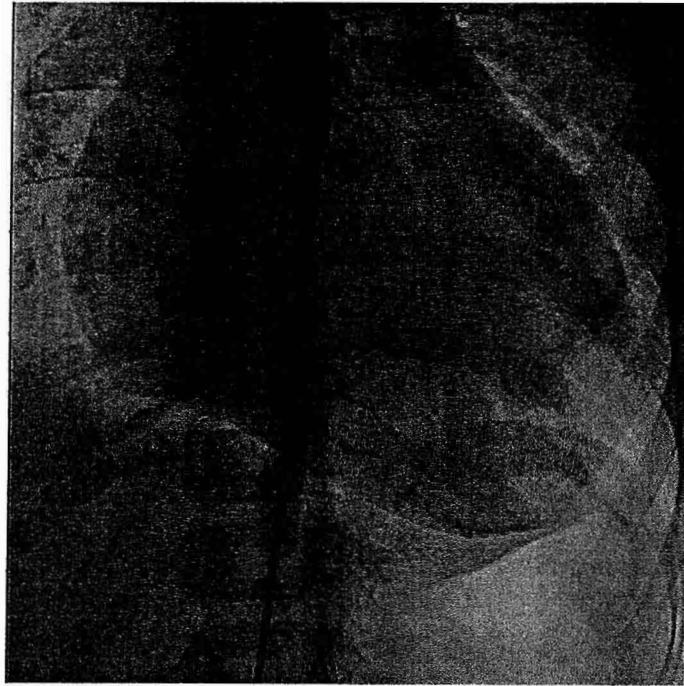


Figure 4

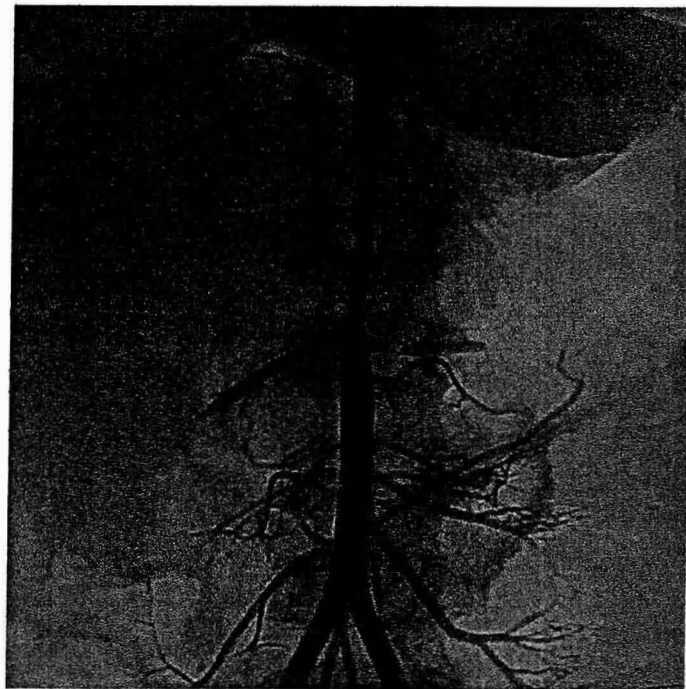


Figure 5

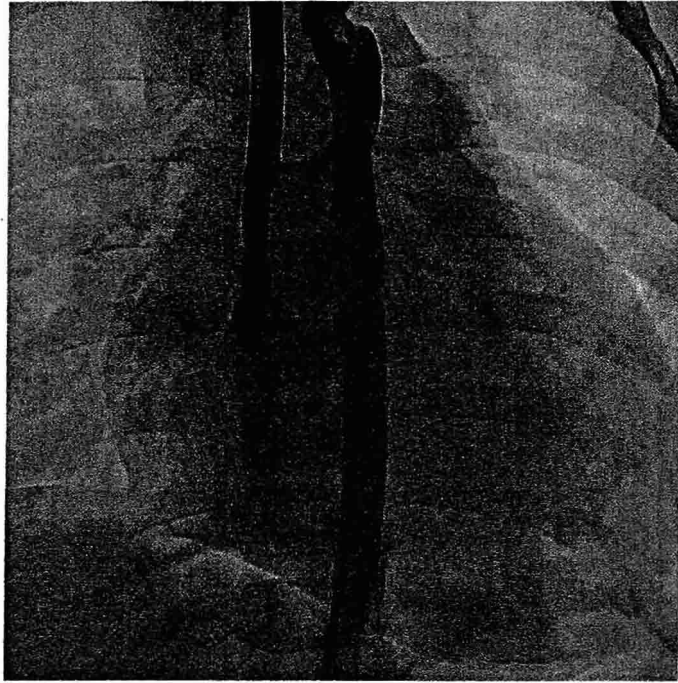


Figure 6




Figure 7

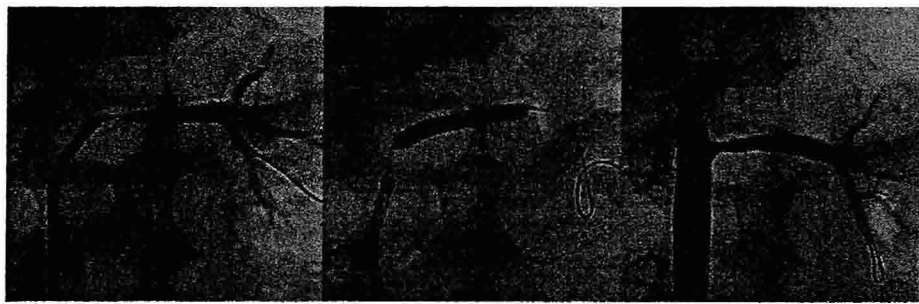


Figure 8